

# Hyperbaric Oxygen Treatment Restores Sudden Hearing Loss in a Patient with Fabry Disease

Markus C. Frantz<sup>a</sup> Bertram F. Pontz<sup>b</sup> Wolfgang Arnold<sup>a</sup>

<sup>a</sup>Department of Otorhinolaryngology, Head and Neck Surgery, Klinikum rechts der Isar, and

<sup>b</sup>Division of Metabolic Diseases, Children's Hospital, Technical University, Munich, Germany

## Key Words

Fabry disease · Sudden hearing loss · Hyperbaric oxygen treatment

## Abstract

Fabry disease is an X-linked inherited disorder of glycosphingolipid metabolism due to the deficient activity of a lysosomal enzyme,  $\alpha$ -galactosidase A. The resultant systemic accumulation of sphingolipids can lead to progressive and sudden hearing loss alongside renal, cardiac and cerebrovascular complications. Although replacement therapy seems to be beneficial for cochlear function, few data are available regarding treatment of sudden hearing loss. This case report describes the course of a unilateral sudden hearing loss in a young (15-year-old) male patient and its improvement following hyperbaric oxygen treatment.

Copyright © 2008 S. Karger AG, Basel

## Introduction

Fabry disease is an X-linked inherited disorder of sphingolipid metabolism due to the deficient activity of  $\alpha$ -galactosidase A, a lysosomal enzyme [1]. Its incidence is estimated to be up to 1 in 117,000 births [2]. Progressive

glycolipid deposition in the endothelial and smooth muscle cells of the microvasculature of affected patients leads to the narrowing and thrombosis of small arteries and arterioles, with the risk of ischaemic complications involving the brain, heart and kidneys [3, 4]. Moreover, patients affected with Fabry disease have an increased incidence of progressive hearing loss and sudden deafness [5]. Enzyme replacement therapy with agalsidase- $\alpha$  is reported to stabilize and improve hearing in Fabry patients who have not already progressed to severe hearing loss [6, 7]. As few cases with sudden hearing loss are reported [5], no data regarding the treatment and outcome of sudden deafness can be found in the literature. This report describes the case of a 15-year-old boy with Fabry disease, who was affected by a sudden unilateral hearing loss.

## Case Report

A 15-year-old boy was tested positive for Fabry disease at the age of 13 and presented acrodynia, acroparaesthesia and hypohidrosis as main manifestations. There was no detectable  $\alpha$ -galactosidase activity in the blood serum, and the diagnosis was confirmed by molecular genetic analysis. Enzyme replacement therapy with agalsidase- $\alpha$  (Replagal<sup>®</sup>) was started immediately after diagnosis.

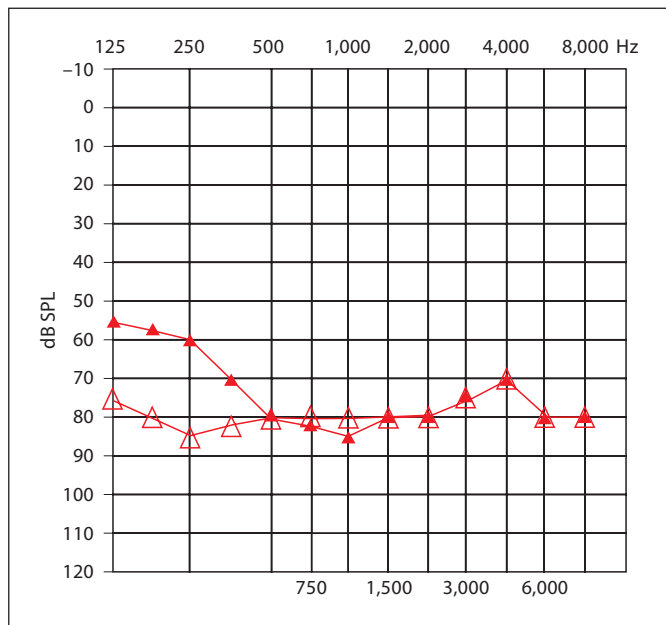
## KARGER

Fax +41 61 306 12 34  
E-Mail [karger@karger.ch](mailto:karger@karger.ch)  
[www.karger.com](http://www.karger.com)

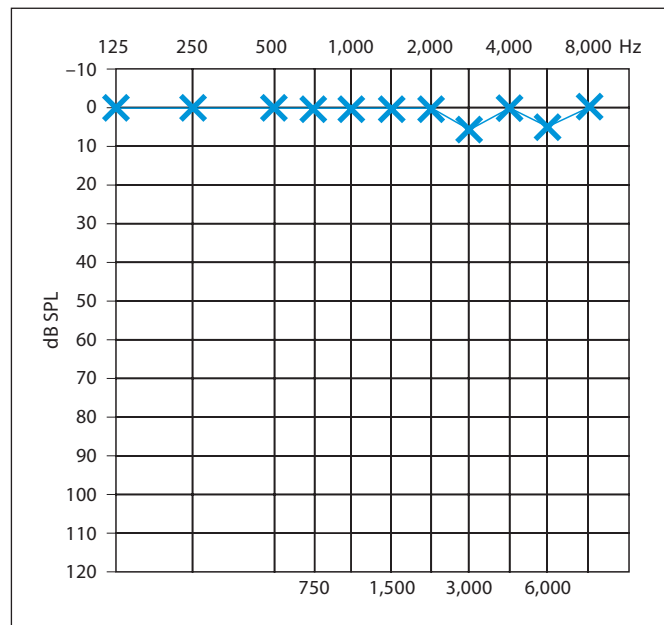
© 2008 S. Karger AG, Basel  
0301-1569/08/0703-0210\$24.50/0

Accessible online at:  
[www.karger.com/orl](http://www.karger.com/orl)

Dr. M.C. Frantz  
Hals-Nasen-Ohrenklinik und Poliklinik  
Klinikum rechts der Isar der Technischen Universität München  
Ismaninger Strasse 22, DE-81675 Munich (Germany)  
Tel. +49 89 4140 2370, Fax +49 89 4140 4853, E-Mail [m.frantz@lrz.tum.de](mailto:m.frantz@lrz.tum.de)



**Fig. 1.** Pure-tone audiometry of the right ear at time of first visit (▲), and following 3 days of infusion therapy (△).



**Fig. 2.** Pure-tone audiometry of the left ear at the time of the first visit, showing normal hearing levels.

The patient was referred for an audiological consultation in the beginning of January 2007. He complained of a right-side total sudden hearing loss and concomitant tinnitus, which had begun 1 week before. He had no other symptoms, such as dizziness, nausea or cephalgia. Otological investigation revealed normal tympanic membranes, the Weber sign was directed to the left side, and a tuning fork placed on the right mastoid was heard on the left side. Pure-tone audiometry of the right ear revealed a sensorineural hearing loss, with a threshold of 55–80 dB between 125 and 500 Hz, and 70–85 dB between 1 and 8 kHz (fig. 1). The pure-tone average on the left side was 5 dB HL (fig. 2). No reproducible transient evoked otoacoustic emissions and no ipsilateral stapedial reflex could be obtained on the right side. Brainstem evoked response audiometry (BERA) showed extended (Jewett V) latency on the right side, and rotational and caloric vestibular testing presented a dysfunction of the right vestibular system.

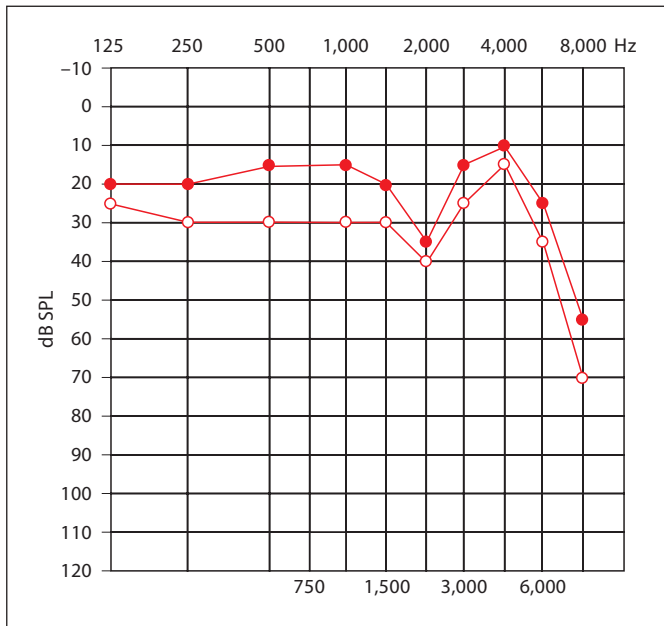
A rheological infusion therapy with prednisolone (250 mg/day) and plasma expanders was started, which lasted for 3 days, and was followed by an oral prednisolone administration. On the third day of therapy, control pure-tone audiometry showed no improvement in hearing (fig. 1). The patient was referred for hyperbaric oxygen treatment on the same day. The hyperbaric oxygen treatment consisted of 15 sessions, each with a duration of 80 min and 1.5 bar pressure of 100% oxygen. The patient reported a subjective improvement in hearing after the 5th session. Control audiometry after 15 sessions showed an increase of hearing threshold to 20–15 dB between 125 and 1,500 Hz, 35 dB at 2 kHz and 10–55 dB between 4 and 8 kHz (fig. 3). Speech audiometry revealed normal understanding for numbers and 85% monosyllabic word recognition at 65 dB in the right ear. The patient had full remission of the right-ear tinnitus. Audiologic control after 2 months showed another 5- to 10-dB gain of hearing loss thresh-

old on the right side (fig. 4), and BERA resulted in normal interpeak latency. Normal stapedial reflex and transient evoked otoacoustic emissions, within the remaining hearing threshold, could now be obtained. During the follow-up, the patient had no re-occurrence of his Fabry manifestations, acrodynia and acroparaesthesia, and presented no other hearing loss. Enzyme replacement therapy was continued throughout the forementioned treatment.

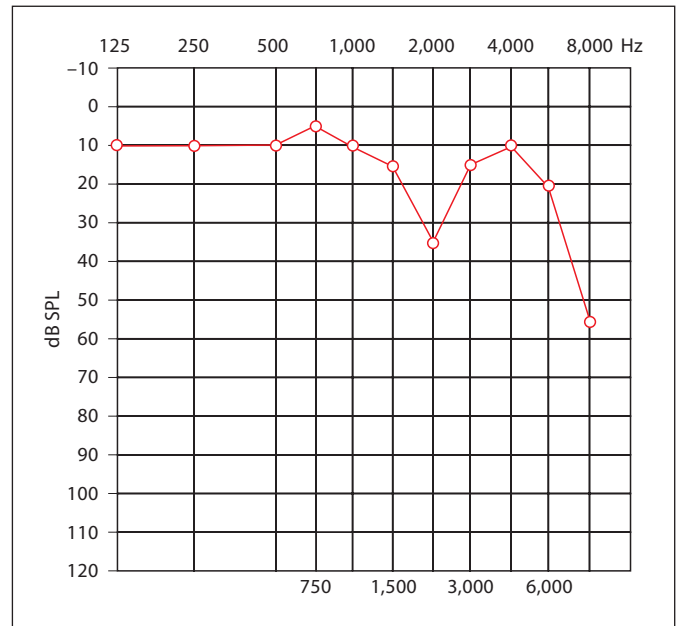
## Discussion

Fabry disease is an X-linked inherited disorder of glycosphingolipid metabolism due to deficient activity of a lysosomal enzyme,  $\alpha$ -galactosidase A [1]. The enzyme deficiency leads to a progressive accumulation of glycosphingolipids (mainly globotriaosylceramide) in plasma and lysosomes throughout the body, resulting in a multiple-system disorder with a wide spectrum of physical signs and symptoms predominantly affecting the nervous system, skin, heart, kidneys and the eyes. Typical initial symptoms include acroparaesthesia and pain crises, hypohydrosis, angiokeratoma and corneal dystrophy, whereas cardiomyopathy, renal failure and cerebrovascular events dominate the life expectancy of Fabry patients [3, 4, 8].

Recently, several studies indicate that hearing loss makes up about 50% of the morbidity of Fabry disease. In



**Fig. 3.** Pure-tone audiometry of the right ear after 7 (○) and 15 (●) sessions of hyperbaric oxygen treatment.



**Fig. 4.** Pure-tone audiometry of the right ear, 1 month after hyperbaric oxygen treatment.

this respect, patients affected by Fabry disease have an increased incidence of progressive hearing loss and sudden deafness [5]. Thus, 57% of 201 male patients and 47% of 165 female patients complained about auditory symptoms, such as tinnitus and progressive or sudden hearing loss [8]. In a cohort of 98 hemizygous males, 78% suffered from high-frequency sensorineural hearing loss [3]. The hearing loss is characteristically severer at high frequencies, and seems to be more pronounced in patients with severe symptoms of Fabry disease, such as renal failure and cerebrovascular lesions [5, 9]. Sudden deafness was reported in 32% of 22 male patients with Fabry disease, often accompanied by tinnitus aurium (27%) [5].

Although a high incidence of progressive and sudden hearing loss has been demonstrated in those studies, only few data are available regarding their treatment. Studies have demonstrated that patients without detectable  $\alpha$ -galactosidase A activity had a more pronounced hearing loss compared to patients with residual enzyme activity [10]. In this respect, enzyme replacement therapy with agalsidase- $\alpha$  is able to stabilize and possibly improve hearing in Fabry patients, who have not already progressed to severe hearing loss [6, 7, 11]. In our case, however, consistent enzyme replacement therapy could not prevent sudden hearing loss of the young patient. Only 1 case report demonstrates an attempt at treating sudden deafness in a patient with Fabry disease, by administering 1 mg/kg prednisone

during 10 days, with no significant recovery [12]. Similarly, in the presented case, therapy with 250 mg/day showed no beneficial effects after 3 days.

The mechanisms of progressive and sudden hearing loss in Fabry patients are still unclear. A histological study of the temporal bones of 2 Fabry patients with bilateral sensorineural hearing loss showed strial and spiral ligament atrophy as well as hair cell loss and a reduced number of spiral ganglion cells [13]. In this respect, it is possible that pathologic changes affect both cochlear and retrocochlear structures. In our case, the extended BERA latency and missing stapedial reflex on the affected side may not only be caused by severe cochlear dysfunction, but could be an indication of additional hypoxic retrocochlear involvement. The latter also showed full recovery, demonstrated by normal BERA and stapedial reflex, following hyperbaric oxygen treatment.

Fabry disease predominantly affects the nervous system, skin, heart, kidneys and the eyes – organs known for their susceptibility to microangiopathic changes. Therefore, an abnormal blood flow is seen in Fabry patients and this can be improved by replacement therapy [14]. Moreover, altered blood vessel properties, caused by glycosphingolipid deposition in the endothelial and smooth muscle cells of the microvasculature, can lead to the narrowing and thrombosis of small arteries and arterioles

with subsequent ischaemic complications of the affected organs [15]. Finally, the accumulation of glycosphingolipids leads to an abnormal blood composition, further altering blood circulation especially in microvasculature [16]. In the presented case, the sudden hearing loss improved following hyperbaric oxygen treatment. In this respect, hyperbaric oxygen treatment seems to be able to reverse early changes caused by ischaemic complications.

In summary, Fabry disease patients show a high incidence of progressive and sudden hearing loss. Whereas progressive hearing loss seems to be influenced by replacement therapy, until now there has been little data concerning treatment of sudden hearing loss. This case report demonstrates the beneficial effects of a hyperbaric oxygen treatment, and that the latter should be prompted when sudden hearing loss occurs. Further studies are necessary to elaborate underlying mechanisms of inner ear involvement in Fabry disease.

## References

- 1 Brady RO, Gal AE, Bradley RM, Martensson E, Warshaw AL, Laster L: Enzymatic defect in Fabry's disease. *Ceramidetrihexosidase deficiency*. *N Engl J Med* 1967;276:1163–1167.
- 2 Meikle PJ, Hopwood JJ, Clague AE, Carey WF: Prevalence of lysosomal storage disorders. *JAMA* 1999;281:249–254.
- 3 MacDermot KD, Holmes A, Miners AH: Anderson-Fabry disease: clinical manifestations and impact of disease in a cohort of 98 hemizygous males. *J Med Genet* 2001;38:750–760.
- 4 Ries M, Ramaswami U, Parini R, Lindblad B, Whybra C, Willers I, Gal A, Beck M: The early clinical phenotype of Fabry disease: a study on 35 European children and adolescents. *Eur J Pediatr* 2003;162:767–772.
- 5 Germain DP, Avan P, Chassaing A, Bonfils P: Patients affected with Fabry disease have an increased incidence of progressive hearing loss and sudden deafness: an investigation of twenty-two hemizygous male patients. *BMC Med Genet* 2002;3:10.
- 6 Hajioff D, Hegemann S, Conti G, Beck M, Sunder-Plassmann G, Widmer U, Mehta A, Keilmann A: Agalsidase alpha and hearing in Fabry disease: data from the Fabry Outcome Survey. *Eur J Clin Invest* 2006;36:663–667.
- 7 Hajioff D, Goodwin S, Quiney R, Zuckerman J, MacDermot KD, Mehta A: Hearing improvement in patients with Fabry disease treated with agalsidase alfa. *Acta Paediatr Suppl* 2003;92:28–30.
- 8 Mehta A, Ricci R, Widmer U, Dehout F, Garcia de Lorenzo A, Kampmann C, Linhart A, Sunder-Plassmann G, Ries M, Beck M: Fabry disease defined: baseline clinical manifestations of 366 patients in the Fabry Outcome Survey. *Eur J Clin Invest* 2004;34:236–242.
- 9 Limberger A, Beck M, Delgado-Sanchez S, Keilmann A: Hearing loss in patients with Fabry disease. *HNO* 2007;55:185–189.
- 10 Ries M, Kim HJ, Zalewski CK, Mastroianni MA, Moore DF, Brady RO, Dambrosia JM, Schiffmann R, Brewer CC: Neuropathic and cerebrovascular correlates of hearing loss in Fabry disease. *Brain* 2007;130:143–150.
- 11 Conti G, Sergi B: Auditory and vestibular findings in Fabry disease: a study of hemizygous males and heterozygous females. *Acta Paediatr Suppl* 2003;92:33–37.
- 12 Barras FM, Maire R: Progressive hearing loss in Fabry's disease: a case report. *Eur Arch Otorhinolaryngol* 2006;263:688–691.
- 13 Schachern PA, Shea DA, Paparella MM, Yoon TH: Otolitic histopathology of Fabry's disease. *Ann Otol Rhinol Laryngol* 1989;98:359–363.
- 14 Moore DF, Altarescu G, Ling GS, Jeffries N, Frei KP, Weibel T, Charria-Ortiz G, Ferri R, Arai AE, Brady RO, Schiffmann R: Elevated cerebral blood flow velocities in Fabry disease with reversal after enzyme replacement. *Stroke* 2002;33:525–531.
- 15 Altarescu G, Moore DF, Pursley R, Campia U, Goldstein S, Bryant M, Panza JA, Schiffmann R: Enhanced endothelium-dependent vasodilation in Fabry disease. *Stroke* 2001;32:1559–1562.
- 16 DeGraba T, Azhar S, Dignat-George F, Brown E, Boutiere B, Altarescu G, McCarron R, Schiffmann R: Profile of endothelial and leukocyte activation in Fabry patients. *Ann Neurol* 2000;47:229–233.